ORIGINAL ARTICLE

Treatment of Common Low Back Pain: A New Approach to an Old Problem

Hemmo A. Bosscher, MD, FIPP*; James E. Heavner, DVM, PhD, FIPP (Hon)*,†

*Department of Anesthesiology, Texas Tech University Health Sciences; †Department of Cell Physiology and Molecular Biophysics, Texas Tech University Health Sciences Center, Lubbock, Texas, U.S.A.

■ **Abstract:** Low back pain is very common, but the pathophysiology is poorly understood. We present a new hypothesis regarding the pathophysiology of common low back pain supported by our flexible endoscopic observations of the epidural cavity (epiduroscopy), anatomic dissection of embalmed and fresh cadavers, and careful review of preexisting information available on the anatomy of the epidural space and neuroforamen. A new approach to the treatment of common low back pain based on the hypothesis was developed and is presented in the case reports of five patients. Treatment focuses on a perichondrium derivative; the peridural membrane, which creates a suprapedicular compartment in the neuroforamen where we hypothesize inflammatory material accumulates. This produces common low back pain by causing inflammation and sensitization of the peridural membrane and periosteum that forms the boundaries of this compartment. Percutaneous Ablation and Curettage and Inferior Foraminotomy (PACIF^{sm}) aims to destroy the peridural membrane, denervate sensitive structures, and remove inflammatory tissues from the suprapedicular canal. The proposed mechanism of action and safety of PACIF^{sm} is discussed in the context of epidural and neuroforaminal anatomy. As shown by the five case reports, PACIF^{sm} appears to be highly effective and safe, warranting further evaluation. ■

Address correspondence and reprint requests to: Hemmo A. Bosscher, MD, FIPP, 3601 4th Street, Lubbock, TX 79430, U.S.A. E-mail: painmgmtdoc@hotmail.com.

Submitted: February 23, 2014; Revised March 28, 2014; Revision accepted: April 15, 2014

DOI. 10.1111/papr.12224

© 2014 World Institute of Pain, 1530-7085/14/$15.00

Pain Practice, Volume 15, Issue 6, 2015 509–517

Key Words: epiduroscopy, low back pain, PACIF, peridural membrane

INTRODUCTION

Low back pain is the most common complaint of patients seen in pain clinics and one of the most common health complaints in the population at large. Clinical examination of patients, computerized tomography, and magnetic resonance imaging frequently reveal conflicting and nonconclusive information. Findings often are not consistent with current ideas about pathophysiological mechanisms producing pain, for example, nerve root compression or irritation. We recently reported that epiduroscopic evaluation of many patients with low back and radiating pain suggests the pain originates in only a few discrete areas within the spinal canal.[1] Specifically, these areas are localized at the inferior aspect of the neuroforamen, at the suprapedicular area of the vertebral body of L5, less frequently at L4, and only occasionally at other levels.[1,2] The symptom complex generated from these areas includes poorly localized diffuse low back pain with a highly variable nonradicular referral pattern. This will be referred to in this article as common low back pain.

Epiduroscopy is a powerful tool that can be used in the treatment of common low back pain.[2] A proposed mechanism of action is destruction of sensitized and inflamed tissue (i.e., peridural membrane) from the suprapedicular areas and interruption of nerve pathways transmitting nociceptive information. Tissue destruction and denervation are accomplished by passing the

epiduroscope into the lateral recess, in close proximity to and over the pedicle into the inferior part of the neuroforamen.[2] The epiduroscope almost completely occupies the suprapedicular space in the neuroforamen. Hence, multiple passes of the epiduroscope back and forth will lead to rupture of membranes and tissue destruction or removal. Hydrostatic force may aid this process but is often not sufficient. Complete passage of the epiduroscope through the suprapedicular canal is necessary. Contact with the periosteum of the pedicle is desirable, as it will increase the probability of a successful outcome.[2] Unfortunately, even mild lateral recess stenosis at the inferior neuroforamen may prevent proper placement of the epiduroscope in some patients in which case treatment is usually unsuccessful.[2] A new procedure presented here was developed to overcome this limitation of epiduroscopy.

The procedure is based on combination of treatments using epiduroscopy, as described recently,[2] and dilator insertion using a transforaminal approach described by Racz et al.[3] The objective of the procedure is to perform Percutaneously Ablation of the peridural membrane and Curettage of the Inferior part of the neuroForamen (PACIF^{sm}).

Description of the Procedure

The procedure is performed in an operating room under sedation. Fluoroscopy is used during the procedure to guide instrument placement and visualize radiopaque contrast spread. Epiduroscopic examination is performed first as previously described.[1,2,4] PACIF^{sm} is attempted from inside to outside with the epiduroscope. If the attempt to enter the inferior foramen is unsuccessful, PACIF^{sm} is carried out using the outside to inside approach. The epiduroscope is used to monitor progression of PACIF^{sm} when carried out outside to inside as a safety measure.

The procedure is performed unilaterally, ipsilateral to the most painful or only painful side. On AP fluoroscopy, the superior endplate of the corresponding vertebral body, usually L5, is placed in parallel to the X-ray beam to delineate the suprapedicular canal superior to the pedicle and inferior to the disc. The medial border of the suprapedicular canal is the main target. The skin is anesthetized approximately midbody of the vertebra cephalad to the target pedicle and 10 to 15 cm lateral to the midline. A combination of AP, lateral, and oblique fluoroscopic views are used to guide advancement of a 20-cm curved epidural needle (RX2—Coude, Epimed). Before use, the needle is bent an additional 20° and 4 cm from the distal tip. The needle is directed caudally and medially toward the pedicle past the lateral border of the pars superior of the facet joint into the suprapedicular canal, the part of the neuroforamen cephalad to the pedicle caudal to the disc. A blunt guide wire is advanced through the needle into the suprapedicular canal and over the pedicle into the anterior epidural space between the dura and posterior longitudinal ligament. Advancement against resistance should be avoided to prevent iatrogenic damage. Correct placement of the wire is confirmed on lateral fluoroscopy. The needle is removed, and a small skin incision is made at the needle insertion site. Next, an 8 to 12 French dilator (Cook) is advanced over the guidewire into the suprapedicular canal and gently advanced into the lateral recess, anterior to the nerve root sleeve, into the ventral epidural space. Close proximity to the pedicle is essential.[2] If needed, the guidewire can be removed and contrast material injected through the dilator to confirm epidural placement. As the procedure is performed under sedation, neurological function can be evaluated during the procedure. Ablation and curettage of tissue in the suprapedicular canal are performed by passing the dilator several times through the suprapedicular canal (Figure 1). Epidurography is performed to confirm patency of the suprapedicular canal and the internal orifice. Hyaluronidase and a mixture of methylprednisolone (Depo-medrol) with local anesthetic are injected through the injection port of the dilator in the suprapedicular area close to the junction of the superior and medial aspect of the pedicle. The dilator is then removed and the entry point covered with a sterile bandage.

CASE REPORTS

Five patients (Table 1) with common low back are presented in whom PACIF^{sm}, either by using an inside-out technique with an epiduroscope or by using the outside-in technique described above.

Patient One

The first patient presented is a 76-year-old female with a history of low back pain. This had been a chronic problem for more than 20 years. She could not recall a precipitating event or injury. She characterized the pain as moderate in intensity, intermittent and burning in nature. The pain was worse with walking and sitting. The pain radiated to the left posterior thigh and hip.

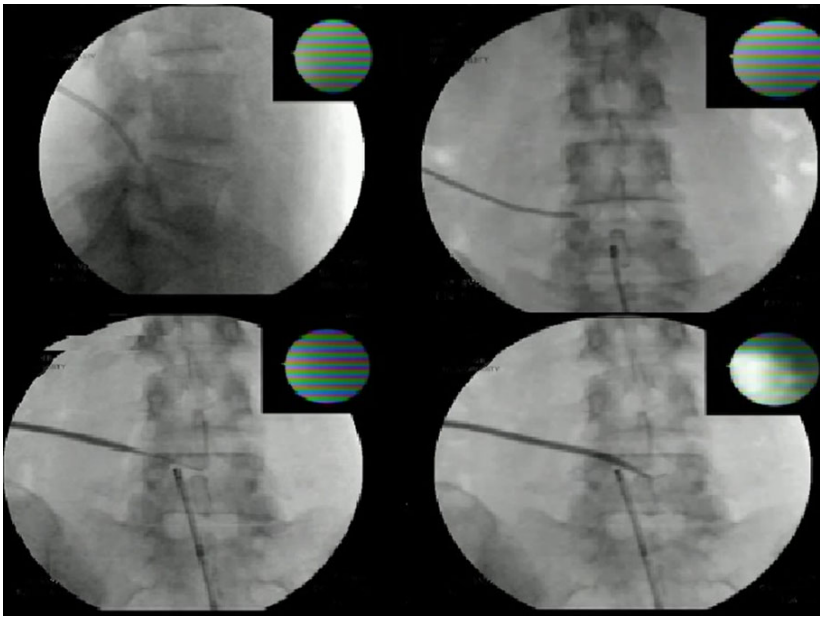

Figure 1. Fluoroscopy imaging of the Percutaneous Ablation and Curettage and Inferior Foraminotomy (PACIF^{sm}) procedure. A curved epidural needle is placed in the inferior aspect of the neuroforamen of L4-5 (top) using a caudomedial approach. A 10 French dilator is advanced over a guide wire into the anterior epidural space (bottom).

Table 1. Patient Information Summary

Patient	Age	Sex	Pain Location	Duration	MRI	PACIF	Pain Relief a	Pain Relief b
One	76	F	Back, left hip and thigh	> 20 years	Spondylosis	Dilator left L5	Good	Excellent
Two	40	F	Back, bil. Thighs, calves	4 years	Small disc bulge L4-5	Dilator left L5	Good	Excellent
Three	37	M	Back, right leg and foot	> 5 years	Spinal stenosis L4/5	Dilator left L5	Good	Good
Four	41	M	Back, bil. hips and legs	3 years	Spondylosis	Epiduroscope bil.	Excellent	Excellent
Five	56	F	Back, hips and left foot	13 years	Unremarkable	Dilator left L5	Excellent	Excellent

Pain relief a, pain relief one month following treatment; Pain relief b, pain relief 3 months following treatment.

She denied weakness or numbness in the lower extremities.

Her medical history is significant for hypertension and a hysterectomy.

Her physical examination showed a normal gait and normal range of motion in the lumbar spine. Her Lasague's, Kemp's, and Faber's tests were negative. Her neurological examination was significant for mild decreased motor strength in the quadriceps muscles. MRI showed moderate spondylosis of the lumbar spine.

Translaminar and transforaminal epidural corticosteroid injections were performed, but only temporary relief was obtained. Epiduroscopy was performed. Pain could be reproduced at the left L4/5 lateral recess. However, lateral recess stenosis and fibrosis at L4/5 prevented access to the suprapedicular area. PACIF^{sm} at L5 on the left was performed using the outside-in dilator technique. At 1-month follow-up, the patient reported excellent pain relief (VAS 2/10). Physical therapy was initiated. At 3-months follow-up, all symptoms had resolved (VAS 0/10). The patient had discontinued all pain medication and function returned to normal.

Patient Two

The second patient presented is a 40-year-old female with a history of low back pain. This had been a chronic problem for more than 4 years. She characterized the pain as severe in intensity, intermittent and aching in nature. The pain was worse with walking and standing. The pain radiated to left and right anterior and posterior thighs and calves. She denied weakness or numbness in the lower extremities. Her medical and surgical histories are unremarkable.

Her physical examination showed a normal gait and normal range of motion in the lumbar spine. Her Lasague's, Kemp's, and Faber's tests were negative. Her neurological examination was normal, without loss of

sensation or decreased motor strength and normal reflexes. MRI showed a small disc bulge at L4/5.

Multiple interventional pain procedures were performed, including lumbar interlaminar and transforaminal epidural corticosteroid injections, median branch blocks, rhizotomy and sacroiliac joint injections. Only temporary relief was obtained. Epiduroscopy was performed. Pain could be reproduced at the left L4/5 lateral recess. However, lateral recess stenosis at L4/5 prevented access to the suprapedicular area. PACIF^{sm} at L5 on the left was performed. At 1-month follow-up, she still complained of some low back pain and stiffness (VAS 2/10). At 3-months, an additional suprapedicular transforaminal epidural corticosteroid injection was performed at the L4 vertebrae on the left. This resulted in complete resolution of symptoms. The patient discontinued all pain medication, and her function returned to normal.

Patient Three

Patient presented is a 37-year-old male with history of chronic left sided low back pain. The pain started many years earlier. No initiating event could be recalled. He characterized his pain as moderate to severe in intensity, constant in time, and burning in nature. The radiation pattern was toward the left buttock, hip, and posterior thigh. Pain worsened by sitting and was relieved with rest. His medical history shows significant hypertension and GERD. His surgical history includes a lumbar discectomy at L4/5 4 years earlier. Multiple interventional pain procedures, including transforaminal epidural corticosteroid injections, posterior rami blocks, rhizotomy, and SCS were performed but failed to reduce his pain.

On examination, his gait was normal. He had full range of motion. There was no tenderness to palpation. The Lasague's and Kemp's tests were equivocal. His neurological examination was normal.

MRI of the lumbar spine showed postoperative changes, moderate central canal stenosis, and mild lateral recess stenosis at L4/5. Epiduroscopy was performed, which showed severe (grade 3) fibrosis and lateral recess stenosis at L4/5.

Percutaneous Ablation and Curettage and Inferior Foraminotomy on the right L5 was performed. Resolution of targeted pain was almost immediate. On 1-month follow-up evaluation, the patient still complained of some diffuse low back pain (2/10). At 3-months follow-up, patient reported back pain, but 80% reduction in overall pain with almost complete return of function. He still required hydrocodone/acetaminophen (7.5 mg/500 mg) daily. The patient was very satisfied with this outcome and would repeat the procedure without reservation.

Patient Four

Patient is a 41-year-old male with a 3-year history of bilateral low back pain radiating to the buttocks, hips, and anterior thighs and feet. The pain was characterized as constant, moderate in intensity, sharp, and stabbing. He could not recall a precipitating event. Pain was worse with sitting and standing. The past medical history included migraine-type headaches and bilateral sinus surgery. On physical examination, the patient had a normal gait and no tenderness to palpation of the spine. Range of motion was limited with respect to flexion/extension and rotation in the back. Bilateral Lasague's and Kemp's tests were positive, Faber's test was negative. MRI showed diffuse spondylosis without spinal stenosis. There was no improvement in response to conservative treatment including medical management, physical therapy, and epidural corticosteroid injection. Epiduroscopy was performed, with concordant pain, some fibrosis, and marked vascularity at the lateral recess and suprapedicular area of L5 on both sides. Excellent access into the suprapedicular canal was obtained with the epiduroscope, so treatment was instituted without doing the external, lateral transforaminal approach with a dilator (ie, multiple passes of the scope through the foramen and injection of hyaluronidase, local anesthetic, and corticosteroid). On follow-up at 1 month, the patient still had some back pain and stiffness but reported overall pain relief to be excellent. At 3-months follow-up, his condition had continued to improve.

Patient Five

Patient is 56-year-old female with 13-year history of low back pain. An initiating event could not be recalled. Her pain radiated to both hips and the left foot. Her pain became severe with activity and was relieved with rest. Her gait was normal. Her neurological examination did not reveal a sensory or motor deficit. Lasague's and Faber's tests were negative. Kemp's test was equivocally positive on the left. MRI studies were not remarkable. Several epidural corticosteroid injections resulted in temporary pain relief only.

On epiduroscopic evaluation, her back pain was reproduced at the lateral recess of L4-5 on the left. Mild lateral recess stenosis prevented treatment using the flexible fiberoptic endoscope. Therefore, a PACIF[sm] procedure was performed at supra-pedicular area of the vertebral body of L5 on the left as described above. At 1-month follow-up evaluation, the patient reported excellent pain relief with marked improvement of function. At 6-months, patient reported absence of any pain and normal function. Patient had discontinued all pain medications and was very satisfied with this outcome.

DISCUSSION

Anatomy of the Inferior Neuroforamen

During epiduroscopy, common low back pain can be reproduced at the inferior neuroforamen of L4-5 and L3-4 in most patients.[1] At this site, vertebral body, pedicle, and pars articularis of the facet joint form the boundaries of a suprapedicular semi-canal. Periosteum covers the pedicle and vertebral body superior to the pedicle. Posteriorly, ligament flavum covers the medial aspect of the canal and periosteum the lateral part. The external orifice of the suprapedicular canal is covered by a fibrous layer, the cribriform fascia, or operculum of Forrestier.[5,6] The internal orifice and roof of the suprapedicular canal is covered by peridural membrane.[7–9] This membrane can be readily demonstrated on microscopic anatomic dissection when a sagittal approach to the spinal canal is used. The membrane originates from perichondrium lining the spinal canal in the human embryo.[10] Preliminary histological investigation using the marker PGP9.5 shows an abundance of unmyelinated nerve fibers in the peridural membrane, similar to the distribution of nerve fibers in periosteum and synovium.[11] This suggests a nociceptive role of the peridural membrane in the spine similar to the role of synovium in joint pain. Indeed, markers for substance P and CGRP have been demonstrated in the lumbar peridural membrane of the rat.[12] The peridural membrane forms an evagination around the exiting nerve root adhering closely to the pedicle superiorly. However, inferiorly, the peridural membrane does not follow the pedicle and creates a triangular suprapedicular compartment (Figure 2), which contains ligaments, connective tissue, and the suprapedicular vessels and nerves.[8,13–16]

The epidural cavity has a rich venous plexus closely associated with the peridural membrane.[10] Blood vessels in this plexus converge to the suprapedicular neurovascular bundle. Discrete nerve branches accompanying the suprapedicular (neuro) vascular bundle have been demonstrated.[17,18] Preliminary investigation suggests these branches originate from the primary posterior ramus of the exiting nerve or its median branch (Figure 2).[19]

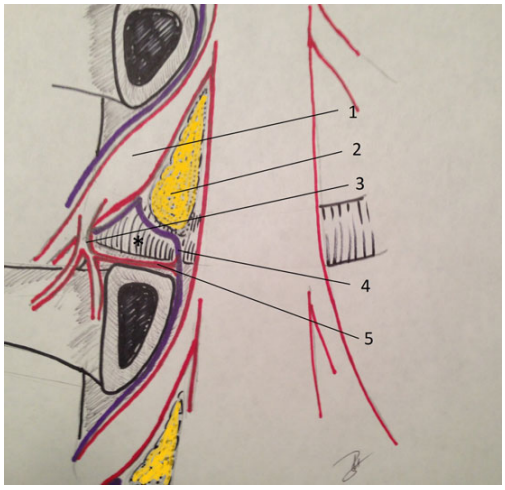

Figure 2. Schematic drawing of the proposed anatomy of the suprapedicular compartment. Red: dura and epineurium. Purple: peridural membrane. * Suprapedicular compartment or suprapedicular canal. 1. Dorsal root ganglion surrounded by the deep evagination of the peridural membrane. 2. Epidural fat in the superficial evagination of the peridural membrane. 3. Posterior primary ramus. 4. Peridural membrane covering the internal orifice of the suprapedicular canal. 5. A branch from the primary posterior ramus or median branch, the suprapedicular nerve innervates periosteum and peridural membrane.

The Pathophysiology of Low Back Pain

Mechanical stresses and strain on the spine are maximal at the L4/5 and L5/S1 level.[20–22] Excessive stresses on the moving parts of the spine result in instability, injury, and an inflammatory response.[15,23,24] Propensity for inflammatory mediators to accumulate at the level of L4-5 depends on a combination of local anatomic factors and gravitational and capillary forces.[1,2,15,20,25]

The origin of these mediators may be nucleus pulposus material from a posterolateral disc rupture, from the adjacent arthritic facet joint, or from a more distant site in the spinal canal.[7,8,15]

A likely explanation of pain evoked by stimulation applied at the interior orifice of the suprapedicular canal is sensitization of the peridural membrane, similar to pain originating from reactive periosteum or synovium such as in an injured bone or joint (Figure 3).[11,26] Sensitization

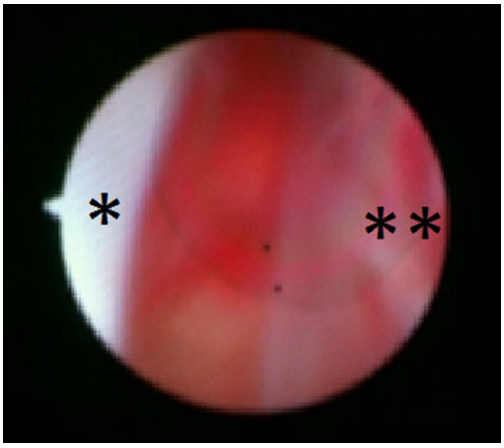

Figure 3. Epiduroscopy image of the L5 nerve root sleeve (*) and peridural membrane (**) at the level of the inferior aspect of the neuroforamen of L4-5 on the right. The nerve root sleeve appears normal, while the peridural membrane appears inflamed. The membrane was highly sensitive to touch with the epiduroscope. The dura overlying the nerve root was not sensitive to touch.

may also extend beyond the suprapedicular area and follow the venous epidural plexus and peridural membrane into the dorsal or ventral epidural cavity. This would explain the effectiveness of epidural corticosteroid application in patients with low back pain.[27]

Proposed Mechanism of Action of the PACIF^{sm}

The precise mechanism by which PACIF^{sm} exerts its effects is unknown. Based on the theory described above, several explanations seem plausible. The dilator is forced through the suprapedicular canal into the lateral recess anterior to the nerve root sleeve and dura. This may disrupt and possibly remove nerve fibers in the neurovascular bundle and nerve branches, which innervate periosteum, peridural membrane, or the cribriform fascia. Inflammatory and fibrotic tissues and inflammatory mediators may be removed reducing sensitization of periosteum and peridural membrane. Disruption of peridural membrane and possible the cribriform fascia allows drainage and absorption of inflammatory substances. In addition, corticosteroid can reach the inflamed and sensitized tissues through the now patent suprapedicular canal.[5] Use of epiduroscopy with PACIF^{sm} is not essential, but advantages include the diagnostic capability of epiduroscopy and an increased margin of safety when the epidural space is observed directly. Likewise, injection of local anesthetic into the foramen is not necessary, but doing so may prevent procedural related pain.

Safety and Complications

The number of patients on whom PACIF^{sm} has been performed is too small to make a statement with respect to safety and complications. However, the *inside-out* technique using epiduroscopy has been performed safely in at least 1,000 patients by the authors. An *outside-in* technique, using a blunt-tipped needle or stiff catheter via a transforaminal approach has been performed frequently for many years with a low complication rate.[3,28] A guidable flexible endoscope, which can pass completely through the foramen has been used safely in the percutaneous transforaminal approach to discectomy in a series of 110 patients.[29] PACIF^{sm} is merely a modification of these procedures and is performed in the "safe" triangle of Kambin[30,31] where the probability of direct damage to the exiting nerve root is minimized. The outside-in approach to PACIF^{sm} was first performed and studied in cadavers by the authors. The procedure was then performed in patients. If mild neuroforaminal narrowing precluded the *inside-out* approach to PACIF^{sm} using the epiduroscope, the outside-in technique of PACIF^{sm} using a dilator was performed under fluoroscopy and direct epiduroscopic observation.

The cost and benefit analysis of PACIF^{sm} should be compared to standard methods in the management of chronic low back pain, such as opioid therapy or back surgery, both of which carry a substantial risk of adverse outcomes.[4,32]

Potential complications include epidural bleeding, dural tear and nerve root, or dorsal root ganglion damage.

Batson's plexus and the internal epidural plexus are easily punctured. Placement of a wire or dilator inside a vein may lead to rupture and has the potential of significant bleeding. Epidural hematoma formation requiring surgical evacuation may occur in the presence of an increased transmural venous pressure gradient. Intravascular injection is common with transforaminal injections but does not lead to major complications in most patients.[33] In general, intravascular placement of the dilator may be avoided if the guidewire moves freely in the anterior epidural space.

Large arteries can be present in the neuroforamen but are unlikely to be punctured with a blunt needle or flexible wire approach. However, proper surgical back up for PACIF^{sm} is recommended.

Compromise of an essential radicular vein or artery may lead to nerve root or even spinal cord dysfunction.[34,35] Considering the large number of interventional

procedures performed in this area, including spine surgery, the probability of this potentially devastating complication is small.

Dural puncture will occur in some patients.[36] Placement of a large dilator may lead to a dural tear. Considering the large number of intraspinal procedures performed, often with sharp instruments, the clinical significance of this complication may be low. Injection of contrast through the dilator may alert the operator to subdural or subarachnoid placement so that further damage to the dura or arachnoid can be avoided.

Direct nerve root damage is possibly the main risk of advancing a relatively large instrument into the spinal canal. However, in the absence of severe lateral recess stenosis, the intradural nerve root floats freely at the level of the suprapedicular canal but is fixed in the dural orifices, which are located at the inferior aspect of the adjacent pedicles. This allows the nerve root to be moved by the dilator (Figure 4). In addition, sharp instruments are not used inside the spinal canal with PACIF. Therefore, cutting damage to the nerve root, even when instruments are placed in the subarachnoid space, is unlikely. It is recommended that the patient is kept responsive during the procedure; frequent neurological testing will provide an extra margin of safety.

Pain relief can be profound with this procedure, and patients may become active prematurely after the procedure. To avoid this kind of adverse outcome, postoperative management should include supervised gentle progressive physical therapy.

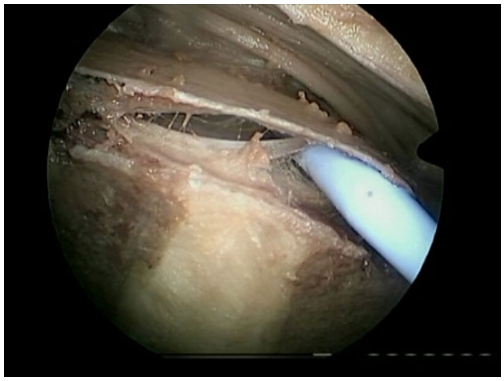

Figure 4. Anatomic dissection of the lumbar spinal canal using a sagittal approach. Left is cephalad. The disc is at L4-5. A 10 French dilator is placed from lateral to medial, through the neuroforamen, over the pedicle into the anterior epidural space. The intradural nerve roots are not compressed.

Critique and Comments

Anatomic details described above can be confirmed and refined by direct dissection and histology using the appropriate stains. Obtaining precise knowledge of the pathophysiology will be more challenging. Classical theory indicates the nerve root and dorsal root ganglion, disc and facet or sacroiliac joint as sources of pain in the majority of patients with low back pain.[37,38] A number of nerve blocking and denervation techniques of the facet joint, sacroiliac joint, or discs are in existence with variable effectiveness and disappointing long-term results.[39] The same is true for percutaneous or open spinal decompression techniques.[31]

Any success with these procedures may be due to mechanism different from what is generally presumed. For example, assuming that the peridural membrane has a function similar to synovium, laminectomy, or discectomy may exert its pain relieving effect through surgical resection of this membrane and not through decompression of a nerve root or dorsal root ganglion. Similarly, RFTC lesioning or laser techniques may provide pain relief through denervation of sensitive tissues in the suprapedicular space rather than through denervation of the facet joint.

Effectiveness of the PACIF may be due to the injection of epidural corticosteroid in the inferior aspect of the neuroforamen and epidural space and not to the mechanical action of PACIF. However, the indication for PACIF is persistent back pain with or without radiating pain that fails to respond to common interventional pain procedures, including trans-laminar and suprapedicular transforaminal corticosteroid injections. In addition, complete passage of the epiduroscope or dilator through the suprapedicular canal is a necessary condition to obtain good pain relief. Application of corticosteroid in the suprapedicular canal, when passage of the epiduroscope or dilator is incomplete, has in general not been effective.[2]

Relief with PACIF can be profound but incomplete. Partial resolution of symptoms may be caused by incomplete removal of inflamed tissue, membranes, periosteum or its innervation at the treated site. As PACIF only treats one site at a time, a plausible explanation for incomplete relief is the presence of additional pathology that has not been treated, such as an area of severe fibrosis after back surgery (third patient),[4] or presence of pathology at an additional level (second patient).

A new interventional approach to the treatment of common low back pain is presented. Consistency and

completeness with respect to the relief of targeted pain suggest a single pathophysiological mechanism of common low back pain, which may include sensitization of a peridural membrane similar in function to periosteum or synovium. Release of inflammatory material from a damaged disc or facet joint, not necessarily local, may lead to accumulation of inflammatory tissue in a suprapedicular semi-canal, and sensitization of this membrane or periosteum. PACIF^{sm} may exert its effect through the removal of sensitized membrane and inflamed tissue and interruption of innervation to these sites. Further basic research will be needed to describe the anatomy and pathophysiology of common low back pain in detail and to explain the mechanism by which PACIF^{sm} exerts its effect.

The number of patients treated with the PACIF^{sm} procedure is small. However, the remarkable pain relief provided to these patients with chronic low back pain refractory to traditional treatments justifies critical evaluation of the technique for possible widespread use.

ACKNOWLEDGEMENTS

The authors would like to thank Claude Lobstein and Anthony Hewetson from the Department of Anatomy, Texas Tech University Health Science Center for their invaluable support.

REFERENCES

1. Bosscher HA, Heavner JE. Diagnosis of the vertebral level from which low back or leg pain originates. A comparison of clinical evaluation, MRI and epiduroscopy. *Pain Pract.* 2012;12:506–512.

2. Bosscher HA, Heavner JE. Lumbosacral epiduroscopy predicts outcome of treatment. *Pain Pract.* 2014;14:506–514.

3. Racz GB, Noe C, Heavner JE. Selective spinal injections for lower back pain. *Curr Rev Pain.* 1999;3:333–341.

4. Bosscher HA, Heavner JE. Incidence and severity of epidual fibrosis after back surgery: an endoscopic study. *Pain Pract.* 2010;10:18–24.

5. Paz-Fumagalli R, Haughton VM. Lumbar cribriform fascia: appearance at freezing microtomy and MR imaging. *Radiology.* 1993;187:241–243.

6. Le Forestier J. *Trou de Conjugaison Vertébral et L'espace Épidural*. Paris: Thèse; 1922.

7. Loughenbury PR, Wadhwani S, Soames RW. The posterior longitudinal ligament and peridural (epidural) membrane. *Clin Anat.* 2006;19:487–492.

8. Wiltse LL, Fonseca AS, Amster J, et al. Relationship of the dura, Hofmann's ligaments, Batson's plexus, and a fibrovascular membrane lying on the posterior surface of the vertebral bodies and attaching to the deep layer of the posterior longitudinal ligament: an anatomical, radiologic, and clinical study. *Spine (Phila Pa 1976).* 1993;18:1030–1043.

9. Ansari S, Heavner JE, McConnell DJ, Azari H, Bosscher HA. The peridural membrane of the spinal canal: a critical review. *Pain Pract.* 2012;12:315–325.

10. Dunn P, Girardin M. Embryological study of the spinal dura and its attachment into the vertebral canal. *Int J Osteopath Med.* 2006;9:85–93.

11. Hukkanen M, Konttinen YT, Rees RG, Santavirta S, Terenghi G, Polak JM. Distribution of nerve endings and sensory neuropeptides in rat synovium, meniscus and bone. *Int J Tissue React.* 1992;14:1–10.

12. Kumar R, Berger RJ, Dunsker SB, Keller JT. Innervation of the spinal dura. Myth or Reality? *Spine.* 1996;21:18–26.

13. Luschka H. *Die Nerven Des Menschlichen WIRBELKANALS*. Tubingen: Laupp; 1850.

14. Hovelaque A. Le nerf sinu-vertebral. *Ann Anat Pathol.* 1925;5:435–443.

15. Friberg S, Hirsch C. Anatomical and clinical studies on lumbar disc degeneration. *Acta Orthop Scand.* 1949;19:222–242.

16. Breit S, Giebels F, Kneissl S. Foraminal and paraspinal extraforaminal attachments of the sixth and seventh lumbar spinal nerves in large breed dogs. *Vet J.* 2013;197:631–638.

17. Groen GJ, Baljet B, Drukker J. The innervation of the spinal dura mater: anatomy and clinical implication. *Acta Neurochir (Wien).* 1988;92:39–46.

18. Edgar MA, Ghadially JA. Innervation of the lumbar spine. *Clin Orthop Relat Res.* 1976;115:35–41.

19. Pedersen HE, Blunck CF, Gardner E. The anatomy of lumbosacral posterior rami and meningeal branches of spinal nerve (sinu-vertebral nerves); with an experimental study of their functions. *J Bone Joint Surg Am.* 1956;38-A:377–391.

20. Nixon J. Intervertebral disc mechanics: a review. *J R Soc Med.* 1986;79:100–104.

21. Nachemson AL, Schultz AB, Berkson MH. Mechanical properties of human lumbar spine motion segments. Influence of age, sex, disc level and degeneration. *Spine.* 1979;4:1–8.

22. Iyer S, Christiansen BA, Roberts BJ, et al. A biomechanical model for estimatin loads on thoracic and lumbar vertebrae. *Clin Biomech (Bristol, Avon).* 2010;9:853–858.

23. Modic MT, Ross JS. Lumbar degenerative disk disease. *Radiology.* 2007;245:43–61.

24. Raj P. Intervertebral disc: anatomy-physiology-pathophysiology-treatment. *Pain Pract.* 2008;8:18–44.

25. Hamid M, Toussaint PJ, Delmas V, et al. Anatomical and radiological evidence for the iliolumbar vein as an inferior lumbar venous system. *Clin Anat.* 2007;20:545–552.

26. Grönblad M, Liesi P, Korkala O, Karaharju E, Polak J. Innervation of human bone periosteum by peptidergic nerves. *Anat Rec.* 1984;209:297–299.

27. Cohen SP, Bicket MC, Jamison D, Wilkinson I, Rathmell JP. Epidual steroids: a comprehensive, evidence-based review. *Reg Anesth Pain Med.* 2013;38:175–200.

28. Park KD, Lee J, Jee H, Park Y. Kambin triangle versus the supraneural approach for the treatment of lumbar radicular pain. *Am J Phys Med Rehabil*. 2012;91:1039–1050.

29. Ditsworth DA. Endoscopic transforaminal lumbar discectomy and reconfiguration: a postero-lateral approach into the spinal canal. *Surg Neurol*. 1998;49:588–597.

30. Civelek E, Solmaz I, Cansever T, et al. Radiological analysis of the triangular working zone during transforaminal endoscopic lumbar discectomy. *Asian Spine J*. 2012;6:98–104.

31. Nellensteijn J, Ostelo R, Bartels R, Peul W, van Royen B, van Tulder M. Transforaminal endoscopic surgery for lumbar stenosis: a systematic review. *Eur Spine J*. 2010;19: 879–886.

32. Sullivan MD, Howe CQ. Opioid therapy for chronic pain in the US: promises and perils. *Pain*. 2013;154(Suppl 1): S94–S100.

33. Karaman H, Kavak GO, Tufek A, et al. The complications of transforaminal lumbar epidural steroid injections. *Spine (Phila Pa 1976)*. 2011;36:E819–E824.

34. Henderson FC, Crockard HA, Stevens JM. Spinal cord edema due to venous stasis. *Neuroradiology*. 1993; 35:312–315.

35. Sliwa JA, Maclean IC. Ischemic myelopathy: a review of spinal vasculature and related clinical syndromes. *Arch Phys Med Rehabil*. 1992;73:365–372.

36. Choi G, Lee SH, Raiturker PP, Lee S, Chae YS. Percutaneous endoscopic interlaminar discectomy for intracanalicular disc herniations at L5-S1 using a rigid working channel endoscope. *Neurosurgery*. 2006;58(Suppl 1):ONS59–ONS68.

37. Bogduk N, Wilson AS, Tynan W. The human lumbar dorsal rami. *J Anat*. 1982;134:383–397.

38. Mixter WJ, Barr JS. Rupture of the intervertebral disc with involvement of the spinal cord. *N Engl J Med*. 1934;211:210–214.

39. Chou R. Low back pain (chronic). *Clin Evid (Online)*. 2010; pii:1116.